

Multicenter Evaluation of the Breast Lesion Excision System, a Percutaneous, Vacuum-Assisted, Intact-Specimen Breast Biopsy Device

Angela Sie, MD¹
 David C. Bryan, MD²
 Victor Gaines, MD³
 Larry K. Killebrew, MD⁴
 Christine H. Kim, MD⁵
 Carrie C. Morrison, MD⁶
 William R. Poller, MD⁷
 Ada P. Romilly, MD⁸
 Kathy Schilling, MD⁹
 Janet H. Sung, MD¹⁰

¹ Long Beach Memorial Breast Center, Long Beach, California.

² Hill Breast Center, Pasadena, California.

³ Vassar Brothers Breast Center, Poughkeepsie, New York.

⁴ Oklahoma Breast Care Center, Oklahoma City, Oklahoma.

⁵ Polak Breast Diagnostic Center, Torrance, California.

⁶ St. John's Mercy Breast Center, St. Louis, Missouri.

⁷ Allegheny General Breast Center, Pittsburgh, Pennsylvania.

⁸ H. Lee Moffitt Cancer, Tampa, Florida.

⁹ Center for Breast Care, Boca Raton, Florida.

¹⁰ Windsong Radiology, Buffalo, New York.

Part of this study was presented at the Radiological Society of North America (RSNA), November 2004.

Dr. Killebrew is a shareholder in and consultant for the Intact Medical Corporation.

Informed consent was obtained before each procedure.

Address for reprints: Angela Sie, MD, Long Beach Memorial Breast Center, 701 East 28th St., Suite 200, Long Beach, CA 90806; Fax: (562) 933-7869; E-mail: asie@memorialcare.org

Received February 13, 2006; revision received May 4, 2006; accepted May 15, 2006.

BACKGROUND. Percutaneous, vacuum-assisted, large-gauge core needle biopsy (VACNB) provides an alternative to open surgical biopsy as an initial diagnostic tool for breast lesions, yet rates of underestimating malignant diagnoses remain sufficiently high to warrant surgical biopsy in some cases. The current study was performed to determine if the Breast Lesion Excision System (BLES) provides a feasible alternative to VACNB.

METHODS. A retrospective review was conducted of 742 consecutive mammographic lesions with microcalcifications classified as Breast Imaging Reporting and Data System (BIRADS) IV or V that had stereotactic percutaneous biopsy using BLES. Initial diagnoses obtained from the histopathologic examination of tissues retrieved at biopsy were compared with the histopathologic examination of tissues received from surgical excision or lumpectomy. Underestimation rates for atypical ductal hyperplasia (ADH) and ductal carcinoma in situ (DCIS) were recorded if open surgical biopsy revealed DCIS or invasive cancer, and invasive cancer, respectively.

RESULTS. Of the 742 breast lesions, 34 displayed ADH upon biopsy with the BLES device. Two patients did not receive open surgical biopsy. Of the 32 patients who had open surgical excision, 3 (9.4%) had DCIS or invasive cancer. There were 119 diagnoses of DCIS upon biopsy with the BLES device. Four patients did not receive open surgical biopsy. Of the 115 patients who had open surgical excision, 6 (5.2%) had invasive cancer.

CONCLUSIONS. Breast biopsy can be performed accurately using the BLES device. Compared with VACNB, it does not alter the need for surgical excision in women diagnosed with ADH or DCIS at core biopsy. *Cancer* 2006;107:945-9. © 2006 American Cancer Society.

KEYWORDS: breast biopsy, vacuum-assisted biopsy, radiofrequency-assisted biopsy, invasive ductal carcinoma, ductal carcinoma in situ, DCIS, atypia, atypical ductal hyperplasia, ADH.

Since its introduction, percutaneous biopsy has provided a simple, relatively inexpensive, and cosmetically agreeable alternative to open surgical biopsy for the assessment of suspicious breast lesions.¹ Percutaneous biopsy affords prompt diagnoses and for many women obviates the need for surgery. Percutaneous core biopsy devices use large-gauge needles and sometimes vacuum assistance. To obtain sufficient material for diagnostic purposes, these devices typically require multiple core tissue samples, ranging from 3 to 20 in number.^{2,3}

Underestimation rates of atypical ductal hyperplasia (ADH) and ductal carcinoma in situ (DCIS) have been used to determine

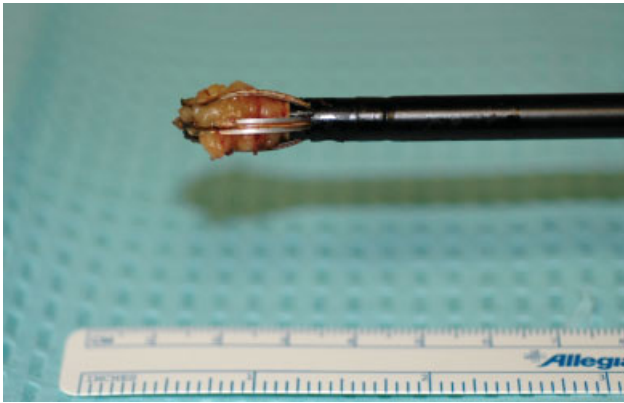


FIGURE 1. The 10-mm wand from the Breast Lesion Excision System.

the accuracy of the percutaneous breast biopsy techniques.⁴⁻⁶ Currently, underestimation rates range from 10% to 50% for ADH²⁻¹⁸ and 4% to 28.6% for DCIS^{2,3,5,7,9,10,12,14-18} for percutaneous, vacuum-assisted, large-gauge core needle devices (VACNB).

The Breast Lesion Excision System (BLES) is an automated, vacuum-assisted breast biopsy device (Fig. 1). The BLES biopsy procedures are done with a single pass. Upon entry into the breast, radiofrequency is used to ablate breast tissue. At the lesion site, the retrieval basket is deployed to circumscribe the lesion. Once captured, the specimen-containing basket and wand are removed from the incision site, generally 6–8 mm (Fig. 2). Image guidance for the BLES device can be either sonographic or stereotactic.

This study was done to calculate the underestimation of pathology in women with a primary diagnosis of ADH or DCIS who underwent the BLES biopsy procedure for microcalcifications. We report the findings of a multiinstitutional retrospective review of stereotactic biopsy procedures using the BLES. Open surgical biopsy was recommended on all patients with ADH or DCIS. Underestimation rates were calculated based on the discordance in diagnoses between percutaneous biopsy and open surgical biopsy for ADH and for DCIS.

MATERIALS AND METHODS

Institutional Review Board approval or official waiver was obtained from each participating clinic. Informed consent from each patient was obtained before her procedure; however, patient approval or informed consent was not required for the retrospective review of patient records.

A retrospective review was performed of 742 consecutive breast lesions with microcalcifications classified as BIRADS IV or V using the Breast Imaging

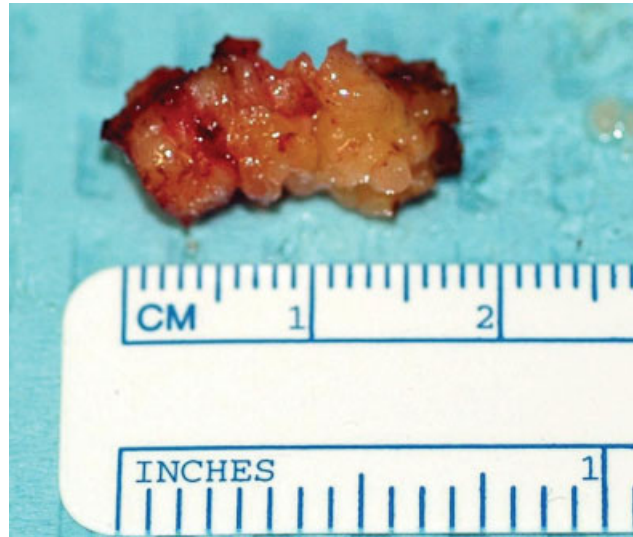

FIGURE 2. Representative sample of intact breast lesion removed during biopsy with the Breast Lesion Excision System with a 10-mm wand. Sample was approximately 18 mm in length.

Reporting and Data System.¹⁹ All had stereotactic biopsy using the BLES (Intact Medical, Natick, MA). Fourteen radiologists from 10 clinical facilities contributed breast lesion data collected from November 15, 2002, to September 1, 2004. No patient-specific identifiers were used or recorded in the data collection. Physicians at each institution had their own criteria for selecting lesions for biopsy. Procedural diagnostic data were contributed by participating radiologists while surgical diagnostic data were supplied by the managing surgeon. At each site, data from the first 15 patients on which the BLES device was used were classified as training due to the presence of the instructional clinical team from Intact Medical during the procedures. These data were excluded from our study. Further exclusion criteria included patients whose breasts compressed to less than 2.5 cm during the biopsy procedure and patients with any implantable electronic devices, such as cardiac pacemakers. Use of the BLES on patients who met such exclusion criteria is not recommended by the manufacturer, and they were therefore offered an alternative diagnostic procedure and excluded from our study. Inclusion criteria included patients whose mammograms showed microcalcifications classified as BIRADS IV or V and patients who received stereotactic biopsy using the BLES device. Stereotactic biopsy techniques and imaging equipment remained constant throughout the study period. The goals for the biopsies were to retrieve representative diagnostic specimens and not necessarily remove the entire mammographic finding. Typically, 1 intact spe-

TABLE 1
Number of Biopsies Contributed by Each of 14 Participating Physicians Resulting in 742 Procedures

Physician	Number of biopsies	Percent of total number of biopsies
A	37	5.0
B	30	4.0
C	49	6.6
D	60	8.1
E	27	3.6
F	38	5.1
G	42	5.7
H	48	6.5
I	105	14.2
J	22	3.0
K	66	8.9
L	112	15.1
M	44	5.9
N	62	8.4

cimen was removed with the BLES device. More than 90% of the specimens were removed using a 10-mm wand, and the remaining specimens were removed using a 15-mm wand.

Biopsies were performed by board-certified radiologists, and biopsy samples were analyzed by pathologists at participating clinical sites. Stereotactic guidance was performed using the Fischer *Mammotest* table (Fischer Imaging, Denver, CO) at 5 centers and the LORAD Multi Care Stereo Table (Hologic, Bedford, MA) at 5 centers. Primary pathology diagnoses included benign lesion, ADH, atypical lobular hyperplasia (ALH), DCIS, invasive ductal carcinoma (IDC), invasive lobular carcinoma (ILC), lobular carcinoma in situ (LCIS), and other cancer. Benign diagnoses were not further classified. Women with percutaneous diagnoses of ADH or DCIS were offered surgical biopsy. Diagnoses at surgery were recorded and rates of ADH and DCIS underestimations were calculated. An ADH underestimation was recorded, if open surgical biopsy revealed DCIS or invasive cancer. A DCIS underestimation was recorded if open surgical biopsy revealed invasive cancer. Data from each clinical site were tabulated by participating radiologists and transferred to a single spreadsheet (EXCEL, Microsoft, Redmond, WA) for data consolidation and analysis.

RESULTS

All BLES procedures were performed between November 15, 2002, and September 1, 2004, by 14 participating radiologists at 10 clinical sites. A total of 742

TABLE 2
Underestimation Rates for ADH and DCIS Using the BLES Device

	ADH	DCIS
Number of cases diagnosed at biopsy	34	119
Number of cancers diagnosed at surgery	3 IDC or DCIS 21 no ADH or other cancer	6 IDC
Underestimation rate	9.4%	5.2%
Exclusions	2*	4 [†]

ADH indicates atypical ductal hyperplasia; DCIS, ductal carcinoma in situ; BLES, Breast Lesion Excision System; IDC, invasive ductal carcinoma.

* One lost to follow-up and 1 refused surgery.

[†] Two lost to follow-up, 1 refused surgery, 1 deceased before surgery.

BLES biopsy procedures were performed (Table 1). No physician contributed more than 112 procedures (range, 22 [3%]–112 [15.1%], mean 53 [7.3%]).

The positive predictive value was 23.2% using the BLES device. IDC was found in 43 (5.8%), ILC in 6 (0.8%), DCIS in 119 (15.4%), and LCIS in 2 (0.3%) of the procedures. Other cancers recorded at biopsy were 1 case of papillary carcinoma (0.1%) and 1 case of mucinous carcinoma (0.1%).

There were 35 cases of atypia recorded at biopsy. ADH was found in 34 (4.6%) cases and ALH in 1 (0.1%) case. Other benign lesions comprised 535 (72.1%) of the procedures and were not further classified.

Underestimation rates were determined for ADH and DCIS (Table 2). Of the 34 cases of ADH diagnosed at biopsy, 2 were excluded from the analysis as a result of refusal of surgery (1) or loss to follow-up (1). Diagnosis at surgery revealed that 21 of the 32 ADH cases (65.6%) had no residual ADH or cancer present at the target site, whereas 3 cases originally diagnosed as ADH were either IDC or DCIS, resulting in a 9.4% ADH underestimation rate using the BLES device. Of the 119 DCIS cases diagnosed at biopsy, 4 were excluded from analysis. These patients were lost to follow-up (2), refused surgery (1), or died before surgery (1) at the time of data consolidation. Diagnosis at surgery revealed 6 of the 115 DCIS cases were IDC, resulting in a 5.2% DCIS underestimation rate using the BLES device. One patient was downgraded because no residual DCIS was found at surgery.

A low level of radiofrequency-associated thermal artifact was observed along the periphery of most specimens. The size of artifact was not studied but appeared to vary between 0.1 mm and 1 mm in thickness. There were no instances where thermal artifact prevented a definitive diagnosis.

Only 1 adverse event was reported as a result of using the BLES device. This was an infection, which

TABLE 3
Underestimation Rates of ADH and DCIS Based on Size of the Biopsy Device*

Lead author	Device size	ADH underestimation rate [†]	DCIS underestimation rate
Adrales et al., 2000 ⁸	11-gauge needle	9/62 (14.5)	NP
Berg et al., 2001 ¹⁷	11-or 14-gauge needle	2/16 (12.5) [‡]	3/16 (18.8)
Burak et al., 2000 ¹⁵	11-gauge needle	6/46 (13)	10/89 (11.2)
Cangierella et al., 2001 ³	11-gauge needle	2/8 (25)	1/12 (8)
Darling et al., 2000 ¹⁸	11-gauge needle	16/86 (19)	8/175 (10)
Darling et al., 2000 ¹⁸	14-gauge needle	11/28 (39)	8/47 (17)
Grady et al., 2005 ^{4§}	8-gauge or 11-gauge needle	6/47 (13)	NP
Jackman et al., 2002 ⁶	11-gauge needle	22/104 (21)	NP
Jackman et al., 2001 ⁷	11- or 14-gauge needle	13/74 (17.6) [‡]	107/953 (11.2)
Lieberman et al., 1998 ¹⁶	11-gauge needle	1/10 (10)	1/21 (5)
Lieberman et al., 2002 ¹¹	11-gauge needle	11/48 (22.9)	16/119 (13)
Lieberman et al., 2000 ⁹	11-gauge needle	4/17 (23.5)	4/14 (28.6)
Lomoschitz et al., 2004 ⁵	11-gauge needle	2/4 (50)	2/12 (16.7)
Meyer et al., 1999 ¹⁴	11-gauge needle	1/9 (11)	1/28 (4)
Meyer et al., 1999 ¹⁴	14-gauge needle	9/24 (38)	NP (19)
Philpotts et al., 2000 ¹⁰	11-gauge needle	6/26 (23)	9/49 (18)
Pfarl et al., 2002 ¹²	11-gauge needle	6/17 (35.3)	11/91 (12.1)
Pandelidis et al., 2003 ²	11-gauge needle	5/37 (13.5)	12/91 (13.2)
Winchester et al., 2003 ¹³	11-gauge needle	11/65 (17)	NP
Current study	10-mm or 15-mm wand	3/32 (9.4)	6/115 (5.2)

ADH indicates atypical ductal hyperplasia; DCIS, ductal carcinoma in situ; NP, data not provided.

* All studies were performed with stereotactic guidance unless otherwise indicated.

[†] Numbers in parentheses represent percentages. [‡] Number is sum of biopsies performed with 11-gauge and 14-gauge core needles.

[§] Study was performed with ultrasound guidance.

resolved with oral antibiotics. There were no instances of bleeding or hematoma that required additional interventional procedures and no complaints of skin burning as a result of the BLES procedure.

DISCUSSION

VACNB procedures are an established alternative to open surgical biopsy as a diagnostic tool. Typically, underestimation rates of ADH and DCIS have been used as measures of accuracy for these biopsy procedures. In studies by Jackman et al.⁷ and Berg et al.,¹⁷ no significant differences were found in the underestimation rates for ADH or for DCIS when percutaneous biopsy was performed using either an 11G or a 14G vacuum-assisted core needle (Table 3). Darling et al.¹⁸ also found few differences in the underestimation rates for DCIS using either 11G or 14G devices; however, they did report significant differences in underestimation rates for ADH between an 11G device (19%) and a 14G device (39%). Others have reported underestimation rates ranging from 10% to 50% for ADH²⁻¹⁸ and 4% to 28.6% for DCIS.^{2,3,5,7,9,10,12,14-18} Interestingly, Grady et al.⁴ re-

ported a similar underestimation rate for ADH (13%) using either an 8-gauge or 11-gauge ultrasound-guided, vacuum-assisted biopsy device (Table 3).

The current study reports underestimation rates of 9.4% for ADH and 5.2% for DCIS using the BLES device to biopsy a breast lesion. These lower underestimation rates may result from either a reduction in biopsy sampling error or a reduction in interpretation error. Sampling error may occur when a mammographic target region is only partially sampled, rendering an inaccurate pathological diagnosis. Interpretation error may occur when pathological analysis is inaccurate due to poor specimen quality.

Pandelidis et al.² indicated that the key to accurately assessing mammographic lesions is to provide a significant volume of tissue for pathologic analysis. Providing a specimen with intact architecture may be more beneficial than multiple, fragmented core samples. A review of the literature, however, indicates that no studies comparing fragmented core samples with intact samples have been made. Further studies to evaluate this are warranted. Some researchers indicated that the number of core samples does influence the accuracy of VACNB procedures.

Pandelidis et al.² reported that more than 10 core specimens per lesion were required to reduce the ADH underestimation rate. Lomoschitz et al.⁵ found that 12 core specimens from 2 360° probe rotations per lesion yielded the highest degree of accuracy, yet 3 360° probe rotations with up to 20 core specimens still missed diagnosed cancer, underestimated ADH and DCIS, and missed retrieval of calcifications. Liberman et al.¹¹ determined that DCIS underestimation was less likely when the large-gauge core needle device excised all mammographic evidence of the lesion (6.8%) as opposed to when residual mammographic evidence of the lesion (20%) remained within the breast. The DCIS underestimation rates in the current study support the finding by Liberman et al.,¹¹ suggesting that excisional biopsy removal may provide a more accurate diagnosis of DCIS. However, Liberman et al.¹¹ reported an ADH underestimation rate of 18.8% and concluded that ADH underestimation occurred regardless of complete excision at percutaneous biopsy. Sixty-five percent of the ADH lesions in the current study were completely excised during percutaneous biopsy with the BLES device; whether this is of benefit to the patient remains to be determined.

Whereas the underestimations rates for ADH and DCIS reported in the present study appear promising, further study is needed to determine whether obtaining intact specimens instead of fragmented specimens improves the accuracy of underestimation rates of ADH and DCIS. Subsequent to the data acquisition period of the present study, larger wand sizes have been developed. The increase in wand size increases the amount of target tissue retrieved and thus may help to further reduce the underestimation rates for ADH and DCIS. However, this remains to be empirically shown. In the current study, the use of the BLES, however, did not obviate the need for surgical excision in women with a primary diagnosis of ADH or DCIS, but it did provide a reasonable option for percutaneous biopsy of breast lesions presenting with microcalcifications.

REFERENCES

1. Liberman L. Centennial dissertation. Percutaneous imaging-guided core breast biopsy: state of the art at the millennium. *AJR Am J Roentgenol.* 2000;174:1191-1199.
2. Pandelidis S, Heiland D, Jones D, Stough K, Trapani J, Suliman Y. Accuracy of 11-gauge vacuum-assisted core biopsy of mammographic breast lesions. *Ann Surg Oncol.* 2003;10:43-47.
3. Cangiarella J, Waisman J, Symmans WF, et al. Mammotome core biopsy for mammary microcalcification: analysis of 160 biopsies from 142 women with surgical and radiologic followup. *Cancer.* 2001;91:173-177.
4. Grady I, Gorsuch H, Wilburn-Bailey S. Ultrasound-guided, vacuum-assisted, percutaneous excision of breast lesions: an accurate technique in the diagnosis of atypical ductal hyperplasia. *J Am Coll Surg.* 2005;201:14-17.
5. Lomoschitz FM, Helbich TH, Rudas M, et al. Stereotactic 11-gauge vacuum-assisted breast biopsy: influence of number of specimens on diagnostic accuracy. *Radiology.* 2004;232:897-903.
6. Jackman RJ, Birdwell RL, Ikeda DM. Atypical ductal hyperplasia: can some lesions be defined as probably benign after stereotactic 11-gauge vacuum-assisted biopsy, eliminating the recommendation for surgical excision? *Radiology.* 2002;224:548-554.
7. Jackman RJ, Burbank F, Parker SH, et al. Stereotactic breast biopsy of nonpalpable lesions: determinants of ductal carcinoma in situ underestimation rates. *Radiology.* 2001;218:497-502.
8. Adrales G, Turk P, Wallace T, Bird R, Norton HJ, Greene F. Is surgical excision necessary for atypical ductal hyperplasia of the breast diagnosed by Mammotome? *Am J Surg.* 2000;180:313-315.
9. Liberman L, Sama MP. Cost-effectiveness of stereotactic 11-gauge directional vacuum-assisted breast biopsy. *AJR Am J Roentgenol.* 2000;175:53-58.
10. Philpotts LE, Lee CH, Horvath LJ, Lange RC, Carter D, Tocino I. Underestimation of breast cancer with 11-gauge vacuum suction biopsy. *AJR Am J Roentgenol.* 2000;175:1047-1050.
11. Liberman L, Kaplan JB, Morris EA, Abramson AF, Menell JH, Dershaw DD. To excise or to sample the mammographic target: what is the goal of stereotactic 11-gauge vacuum-assisted breast biopsy? *AJR Am J Roentgenol.* 2002;179:679-683.
12. Pfarl G, Helbich TH, Riedl CC, et al. Stereotactic 11-gauge vacuum-assisted breast biopsy: a validation study. *AJR Am J Roentgenol.* 2002;179:1503-1507.
13. Winchester DJ, Bernstein JR, Jeske JM, et al. Upstaging of atypical ductal hyperplasia after vacuum-assisted 11-gauge stereotactic core needle biopsy. *Arch Surg.* 2003;138:619-622; discussion 22-23.
14. Meyer JE, Smith DN, Lester SC, et al. Large-core needle biopsy of nonpalpable breast lesions. *JAMA.* 1999;281:1638-1641.
15. Burak WE Jr, Owens KE, Tighe MB, et al. Vacuum-assisted stereotactic breast biopsy: histologic underestimation of malignant lesions. *Arch Surg.* 2000;135:700-703.
16. Liberman L, Smolkin JH, Dershaw DD, Morris EA, Abramson AF, Rosen PP. Calcification retrieval at stereotactic, 11-gauge, directional, vacuum-assisted breast biopsy. *Radiology.* 1998;208:251-260.
17. Berg WA, Arnoldus CL, Teferra E, Bhargavan M. Biopsy of amorphous breast calcifications: pathologic outcome and yield at stereotactic biopsy. *Radiology.* 2001;221:495-503.
18. Darling ML, Smith DN, Lester SC, et al. Atypical ductal hyperplasia and ductal carcinoma in situ as revealed by large-core needle breast biopsy: results of surgical excision. *AJR Am J Roentgenol.* 2000;175:1341-1346.
19. American College of Radiology (ACR) Breast Imaging Reporting and Data System (BIRADS), 3rd ed. Reston, VA: American College of Radiology, 1998.